

# uveitis



## Steroids in Uveitis

2007



© 2007 Uveitis Information Group

ADVERTISEMENT

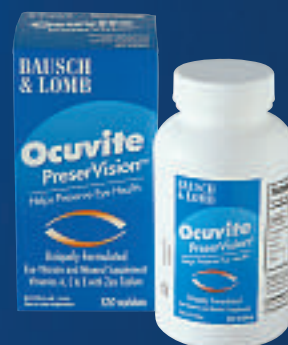# Helps preserve eye health

**At last, the formulation used in a major 10 year eye health trial is available on the UK**

- OcuVite PreserVision is a unique antioxidant vitamin and mineral formula, developed in conjunction with the National Eye Institute in the USA to help preserve vision.
- OcuVite PreserVision contains high amounts of beta-carotene, Vitamin C and E and the mineral zinc, and should be considered in individuals concerned about age-related degeneration of eye health.
- High levels of the eye-protective antioxidants beta-carotene, vitamins C and E and the mineral zinc have been shown to be of benefit to certain individuals, which means that a specific combination of antioxidant ingredients can help preserve eye health.

**Antioxidant Vitamin & Mineral  
Supplement for Eye Health**

**OcuVite**  
**PreserVision™**



“Steroids are horrible!!” “Steroids are ruining my body!” Nearly every patient with uveitis has got her or his experience with “steroids”. In case of mild anterior uveitis, topical treatment with drops or ointment probably causes no problems. Unfortunately, more severe forms, but also most of the intermediate and posterior forms of uveitis, are not effectively treated by topical steroids. Often patients find their individual side effects. So, there are a whole bunch of questions and misunderstandings surrounding this drug. This edition of *uveitis* will help to increase your knowledge about steroids: How do they work? What kind of topical steroids are available in Europe? We will learn that the side effects of steroids mostly depend on the form they are applied, the duration of treatment and the intensity. What are the side effects, how can we avoid them? We also will clarify when steroids should be substituted by immunosuppressives. Children especially are very sensitive to long-term steroid treatment, which tends to lead to an earlier start of immunosuppressive treatment.

In most uveitis patients steroids are unavoidable but the physician should always try to discontinue this treatment or limit it to a tolerable minimal dosage.

Finally we will conclude this issue with the views of 3 people, involved in this treatment: “**Thoughts about Steroid Treatment for Uveitis**” will summarize the experience of an Ophthalmologist, an ophthalmic nurse and a uveitis patient. We hope that all readers can find usable information for their future steroid treatment from this journal.

How was uveitis treated, before in the 50’s of the last century steroids entered ophthalmology? We look back to 1910, when Dr. Andrew Wilson summarized his knowledge about this disease.

Since 2003 the German Patient Interest Group (**DUAG**) has provided 6 awards for uveitis research. Various studies show that useful drugs, which were under investigation, have already found their way into modern treatment principles. Last years awards will be described in detail here.

**Manfred Zierhut,**

Professor of Ophthalmology, University Eye Clinic of Tübingen,  
Germany, august 2007



# Content

- P. 5** **History and Effects of Corticosteroids** This edition about “Steroids” will start with some historical remarks by **Prof. Antonio Secchi**, Padua, Italy, followed by explanations about the effect of steroids on general and ocular inflammation.
- P. 9** **Steroid Eye Drops** The first drugs for an effective treatment of anterior uveitis are steroid drops or ointment. **Pierre-Yves Robert**, ophthalmologist in Limoges, France, will describe what you should know about the various formulations.
- P. 14** **Periocular and Intraocular Steroid Treatment** Besides severe forms of anterior uveitis, all inflammation of the posterior segment of the eye will need a higher dosage of steroids, which can be applied by injection around the eye or even inside. Recently also a steroid releasing device has reached ophthalmology. All you should know about these will be reported by **Prof. Carlos Pavesio** from London.
- P. 18** **Side Effects of Corticosteroids** Unwanted effects may be encountered with steroid therapy. **Prof. Ilknur Tugal-Tutkun** from Istanbul, Turkey, will summarize what we have to be aware of when using steroids for uveitis.
- P. 22** **Use of Corticosteroids in Children with Uveitis** Probably the most challenging group of uveitis patients are children. **Prof. Arnd Heiligenhaus** and **Carsten Heinz**, Uveitis Center in Münster, Germany, will summarize the updated concept for a steroid therapy in these children, but also its limitation.
- P. 27** **Thoughts about Steroid Treatment for Uveitis** Different people may have completely different impressions about steroid treatment. We have asked a patient, an ophthalmic nurse and an ophthalmologist.
- P. 33** **Patients – Two patients report on their Experiences with Steroid Treatment** Today, patients from Italy and Germany describe their story about the positive and negative feelings under steroid treatment.
- P. 37** **News from the Scientific World – Uveitis Awards of the German Patient Interest Group (DUAG) 2005** In 2005 for the third time, the **DUAG** has provided 6 awards for clinical and experimental uveitis research. This report describes the award finding process and the content of the awarded work.
- P. 51** **Cultural Corner – A Look back into 1910** Uveitis is not a new disease, and **Phil Hibbert** reports about the amazing knowledge about this disorder app. 100 years ago.
- P. 54** **Patient Groups & Information**

# History and Effects of Corticosteroids

*There is no doubt that, in the history of medicine, few drugs changed both diseases' course and patients' lives to the extent that steroids did in inflammatory diseases.*

**Prof. Antonio Secchi**, Head of the Department of Ophthalmology at the University of Padua, Italy, invites you to a short journey into the history of the development of steroids, and he also will describe how steroids affect inflammation.

## How the Steroid Story began

Rheumatoid arthritis, to name one of the most significant and frequent clinical conditions in this area, changed its often dramatic clinical course substantially when, in 1949, steroids of the first generation became available on the market. Side effects were often important, sometimes very important, but the general outcome of the disease became in a very short time quite different after this new treatment, much better than what both physicians and patients were used to experiencing until a few years before. Other inflammatory diseases beside rheumatoid arthritis began to be treated with the new drugs, generally with good results, although a kind of “**be careful!**” approach soon became apparent: it seemed that steroids do not really influence the cause of the disease; they simply reduce, to a different extent in different clinical conditions, the severity of both

symptoms and signs of the disease. It took several decades to find out that this statement was not completely true: steroids can also cure an inflammatory condition whose pathogenesis is mostly related to immunological events (= immunosuppressive effect), although perhaps more often they are used (incorrectly? correctly? we might spend weeks on this debate, without reaching a safe conclusion) only as symptomatic drugs. It depends mostly on how much and how long the drug is used: low dosages for a short time will likely have only a symptomatic effect.

## Steroids and Ocular Diseases

In the very middle of the 20th century steroids became available in the armamentarium of all physicians treating inflammatory diseases and, on this

occasion at least, ophthalmologists were among the first to use the new therapeutic opportunity. It was at the beginning of the '50s, in fact, that topical preparations of hydrocortisone began to show up on the druggist's shelves, and both systemic and topical steroids began to be used also in inflammatory diseases of the eye.

In the second half of the century the physiological evolution of pharmacology (searching for stronger drugs with lower or even no side effects) involved also steroids, and generation after generation of new drugs appeared on the market. Since it should be understood that a "new" drug does not necessarily imply to be a "better" drug as well, a few points need to be clarified.

### What should we expect by the Use of Steroids in ocular Inflammation?

The aims for the steroid treatment can be the following ones: a fast resolution of the signs, minimal, or, even better, no complications related to the inflammation; a longer interval between (possible) relapses of the disease; few, manageable, or no side effects.

How can these goals be reached? Answering in the most proper way – which is often different in the different clinical conditions, and may be different among different patients showing the same clinical condition – a panel of

other questions come up: when should the therapy be started? Which steroid should be used? How: topical, systemic, parabolbar, intraocular? How much? How long?

The answer to "when" should be: soon enough. When the ophthalmologist has "decided" that "this" specific condition requires the use of steroids, there is usually no reason for postponing the treatment. This "decision", however, must be sound and thoroughly evaluated in advance in each case. Steroids should only be used when other treatment, likely to be less dangerous in view of the steroids' known side effects, would be anticipated not to behave effectively enough in that clinical condition. It is not a simple decision.

### The Problem of Side Effects

At times the (future) price to pay for an adequate use of steroids – in terms of side effects, which may be minimized but almost never avoided – may be too high given the real severity (in the long term) of the disease to be treated. Drug induced complications, in other words, may be more severe than the disease itself. Several subcategories of uveitis, in fact, are certainly annoying for the patient, but not so really severe to balance the risk of a chronic treatment with steroids. To decide whether to start, or not, a steroid treatment is certainly one of the most important points in the

road map of inflammation in general, and of uveitis in particular. Lots of knowledge and specific experience are required for a sound decision from the doctor's part. Lots of understanding and patience must be exerted by the patient. Good sense and feedback/interaction must exist for a positive and rewarding relationship between the two partners.

### Which Steroid should be used?

Latest generation preparations are often thought (sometimes only hoped) to have lesser systemic effects, but not necessarily to be considered "better". "Deflazacort", to name one of the recent drugs, is thought to be less dangerous than prednisone in terms of side effects. The latter's efficacy, however, is considered by many colleagues to be substantially stronger. So, given that equivalent (again not such a simple issue) doses of different steroids should give a similar anti-inflammatory effect, the Ophthalmologist should try to become fully acquainted with a few preparations, and use them in the majority of his/her cases.

### How should Steroids be applied?

The topical application of steroids is the most effective way. This includes paraculbar, subconjunctivally and (only when strictly required) intravitreal

injections. Intravenous application is indicated, when the effect required is necessarily urgent. Orally in most cases of chronic treatment, with a prolonged, slow tapering.

### How much Steroid should be used?

Again, the answer should be: enough. The writer of these lines is strongly convinced that many cases of chronicization of inflammatory diseases like uveitis are due, at least partially, to treatment often not adequate at the beginning of the disease. Too little cortison, for a short time, with a tapering too fast, may result in an "apparent" healing of the disease, which will "resurface" after a short interval, and slowly become chronic.

That is the main reason why the decision of starting steroids as a therapy should be weighed very carefully. If the decision is "yes", the initial amount of drug, the length of the treatment, the slowness of tapering must be adequate. If not adequate, a relapse of the inflammation will be very often only a matter of time, and chronicization will likely follow.

### How long should Steroids be used?

This is probably the most difficult question to answer, and the usual suggestion of going ahead with the

# Title

therapy for at least two months without inflammatory signs, must be taken for what it is: just a suggestion.

## How do these Drugs work?

An extensive answer to this question could be very complicated. Generally speaking, inflammation is the result of a net of interactions which eventually lead to an extensive damage of cell membrane permeability. Two thousand years ago the Romans had already clear ideas on the matter: inflammation is made of

### **tumor:**

swelling, due to an effusion of fluids from hyperpermeable vessels,

### **rubor and calor:**

hyperemia and heat, due to vasodilation,

### **dolor:**

pain, not a common symptom in uveitis, although often present in inflammation as due to a stimulation of dedicated receptors, and lastly

### **functio lesa:**

damage to sensible targets made by (often relapsing) inflammatory phenomena.

Steroids do limit or block the appearance at the inflammation sites of the chemical mediators (mostly “cytokines”) which make the net of interactions start, or get itself going in a relapsing or in a continuous, chronic way. This effect is obtained through the

inactivation of specific cells (amongst others macrophages, monocytes, lymphocytes, leukocytes, fibroblasts, endothelial cells), which are responsible for the formation and activation of the specific mediators. Steroids turn off, in very few words, a switch that the inflammatory agent had turned on initially – or that will be turned on again to trigger a relapse of inflammation. The inflammation will subside if the treatment was carried out properly in terms of “which steroid”, “how”, “how much” and “how long” – without, or with minimal damage if the therapy was started soon enough. The signs and the symptoms of inflammation will, on the contrary, relapse if the treatment was not adequate in terms of timing, dosage, length, tapering.

## Conclusion

It is the doctor’s responsibility, and the patient’s as well when it comes to compliance, to use when necessary these powerful drugs called steroids in the most proper and effective way. They may do “miracles”, only if thoroughly known, and used in each case with the confidence and the respect they actually deserve.



# Steroid Eye Drops

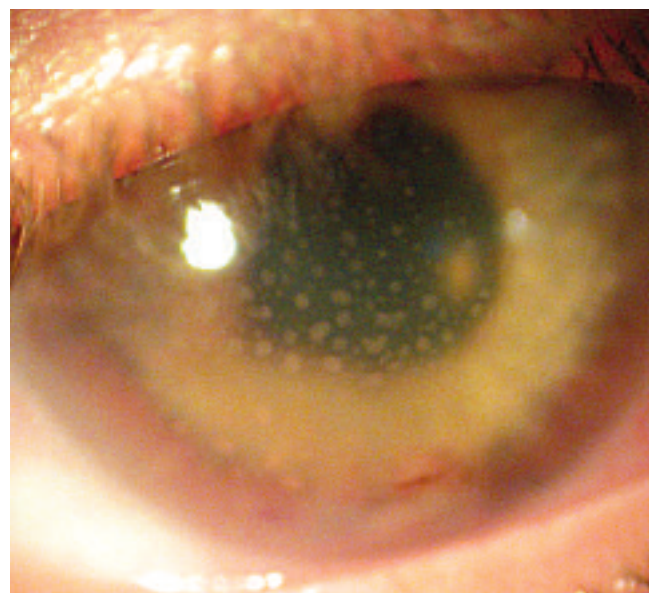
The first step for an effective treatment of anterior uveitis is topically applied steroid drops. Twenty years ago, steroid eye drops were the only treatment for a number of eye diseases. In this article, **Pierre-Yves Robert**, ophthalmologist from Limoges, France, describes the differences between the various steroid drugs, their main indications, and how they should be applied to the eye.

## Are all Steroid Eye Drops the same?

Seven steroid molecules have been commercialized to date, some of them in combination with an antibiotic. They differ regarding their anti-inflammatory effect (depends on the type of steroid) and regarding their ability to penetrate the cornea (depends on the chemistry). hydrocortisone and prednisolone (which have the lowest anti-inflammatory action), dexamethasone (which has the highest), fluormetholone and rimexolone (with less influence on intraocular pressure due to minor corneal penetration), and two derived molecules, loteprednol etabonate and medrysone. The difference in their chemistry leads to a different uptake through the cornea, which induces various degrees of elevation of the intraocular pressure, one of the most important side effects.

## When are Steroid Drops indicated in Uveitis?

Local steroid therapy is the standard treatment of every acute anterior intraocular inflammation (*Figure 1*). In this case a steroid, which penetrates the cornea well, e.g. dexamethasone or prednisolone, will be applied. The frequency can reach once an hour, sometimes even a frequency of each half an hour can be indicated. Dose and duration have to be



*Figure 1:*  
Acute anterior uveitis with inflammatory precipitates on the backside of the cornea (endothelium)

adapted to the course of intraocular inflammation and to eventual side effects. Unfortunately, topical steroids can not reach high concentrations in the vitreous or at the retina. So, in cases of intermediate and posterior uveitis they are only used, when additionally inflammatory cells are found in the anterior chamber.

### Are there Side Effects when topical Steroid Drops are used?

The side effects of topically applied steroids depend on the dosage and the time they will be applied. The major side effects in the eye are glaucoma and cataract induction.

#### ■ Steroid-related Glaucoma

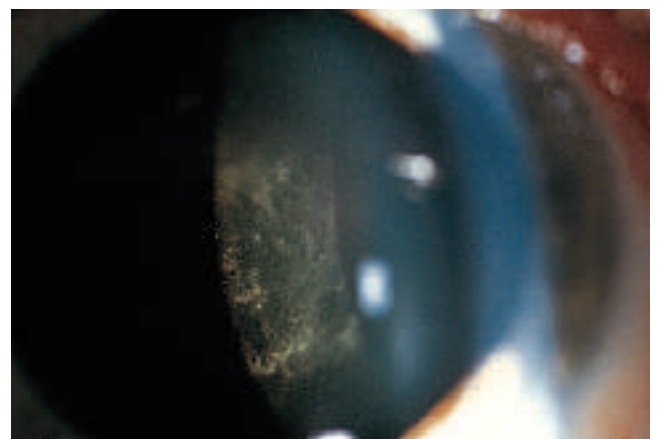
Steroids can raise the intraocular pressure (IOP). A 5mmHg raise is common in young patients after 3 weeks of treatment and can be found in app. 30% of people. This effect is especially noted after local treatments (eye drops, parabolbar or subconjunctival injections). Steroid-related glaucoma develops when this IOP raises more, but it is impossible to predict its delay and seriousness, which can start after a few days or a few months after the beginning of steroid treatment. The reason for the elevation of the pressure problem is found in the outflow system of the eye, the so-called “trabeculum

meshwork”. There, newly formed substances, glucosaminoglycans, fill the gaps, which normally are used for the aqueous humor to leave the anterior chamber. Therefore, prophylaxis of steroid-related glaucoma relies on a strict follow up of IOP in long-term steroid treated patients. This effect is lower with steroids as fluorometholone or rimexolone, which poorly penetrate the anterior chamber.

Nevertheless, these molecules can induce steroid-related glaucoma too, and the same follow-up of IOP is mandatory.

#### ■ Steroid-related Cataract

Long-term steroid therapy induces a typical posterior capsule opacification (*Figure 2*) in 30% to 40% of patients who receive 10mg prednisone during



*Figure 2:*  
*Cataract, induced by steroids*

2 years. This climbs up to almost 100% after 4 years. Specific receptors in lens

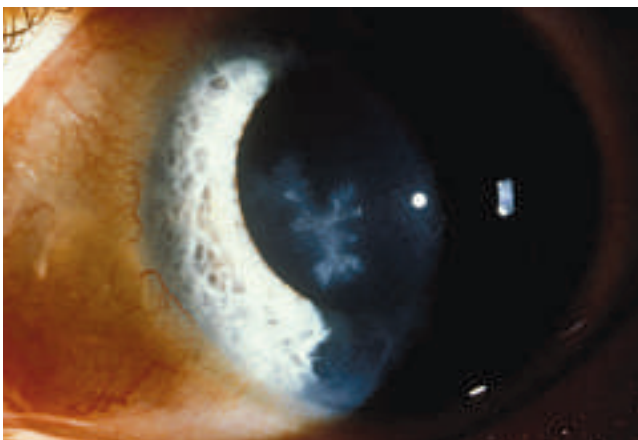
epithelial cells and the susceptibility of these cells to steroids are responsible for the development of lens opacifications.

## ■ Corneal Epithelium Toxicity and Infection

After some time steroid eye drops may weaken corneal epithelium and may promote corneal infections which can result in ulceration. In children, they may thin corneal stroma up to corneal perforation, especially in long-term treatments.

## Contraindications

The essential contraindications of steroid eye drops are acute infections of the ocular surface. Viral (especially acute herpetic, *Figure 3*), fungal, acanthamoeba or bacterial infection that is not under control, is a contraindication for local steroids. For this reason, prescribing steroid eye drops should be reserved to ophthalmologists.



*Figure 3:*  
*Keratitis, due to herpes simplex virus infection.*

## Conclusion

If the inflammation of the eye is located in the anterior part of the eye, local steroid drops are the first line of treatment. The advantage of this treatment is that they reduce ocular inflammation very quickly, without systemic side effects. But used frequently (e.g. every hour) they also can lead to a remarkable steroid concentration in the blood. Their use is limited due to side effects like cataract formation and elevation of the intraocular pressure. So, even topical steroid drugs have to be used carefully and for a defined time.

The following table lists steroid eye drops and ointment, available in some European countries and the USA.

Title

	Hydrocortisone	Prednisolone	Fluorometholone
France		Solucort ophta	Flucon
Germany	Ficortril Hydrocortisone POS	Inflanefran forte Predni-oph Prednisolone- Jenapharm Predni-POS Ultracortenol	Efflumidex Fluoropos Fluoro-Ophtal
United Kingdom	Hydrocortisone	Predsol Predsol N Prednisolone	FML
Italy			Flarex Fluaton Flumetol semplice
Netherlands		Pred forte Ultracortenol Prednisolon	FML Liquifilm Flarex
USA		AK-Pred Econopred Econopred Plus Inflamase Forte Inflamase Mild Pred Forte Pred Mild Prednisol Prednisolone oph	Flarex Fluorometholone oph FML Liquifilm Fluor-Op FML S.O.P. FML Forte Liquifilm Eflone

Table: Steroid eye drops available in France, Germany, United Kingdom, Italy, Netherlands

<b>Dexamethasone</b>	<b>Rimexolone</b>	<b>Loteprednol etabonate</b>	<b>Medrysone</b>
Maxidex	Vexol		
Dexa-EDS Dexamethason- Jenapharm Dexapos, Dexagel Dexa-sine SE Isopto-Dex, Spersadex Totocortin	Vexol	Lotemax	
Maxidex	Vexol		
Etacortilen Luxazone Visumetazone	Vexol	Lotemax	
Dexamethason			
Maxidex Dexamethason  AK-Dex Decadron Ocumeter Dexasol Maxidex Dexamethason oph	Vexol Rimexolone oph	Alrex Lotemax	Medrysone oph HMS

and U.S.A.

# Periocular and Intraocular Steroid Treatment

*Uveitis which involves the anterior part of the eye can be treated with the use of steroid eye drops, but when the back of the eye is involved drops don't penetrate deep enough to treat the inflammation. The use of oral medication is often necessary to treat this posterior type of the disease, but in some situations local treatment is still a good alternative. Prof. Carlos Pavesio who works at the Moorfields Eye Hospital in London, UK, describes the indications and limitations of corticosteroid injections around or inside the eye.*

## What are the Modalities of local Treatment in Uveitis affecting the Back of the Eye?

This form of treatment involves the use of either injections of steroids, which can be delivered around the eye or directly inside the eye, or the use of a device (implant), which is surgically implanted inside the eye and will deliver the medication over a prolonged period of time.

There are two types of injections around the eye: the **orbital floor injection** (Figure 1), which delivers the medication a bit further away from the eyeball, and the **posterior sub-Tenon's injection** (Figure 2), which puts the drug very close to the back of the eye. In both cases the drug will penetrate into the eye by moving through the wall of the eye, called sclera, and reaching the place where the inflammation is taking place inside the eye. However,

the sclera represents a barrier and will limit how much of the medication gets inside the eye.

To bypass this barrier the medication can be put directly inside the eye, and this can be done by an injection or by the device mentioned above. The injection will go through the sclera (eye wall) and put the drug in the posterior compartment of the eye, filled by a gel-like substance, called the vitreous body (Figure 3). The device is implanted by a surgical procedure, which will create a small cut in the sclera and will insert the device into the eye, anchoring it to the eye wall (Figure 4).

## When should this Form of Therapy be considered and when not?

These options should be considered if the uveitis is affecting only one eye, or is much more serious in one of the eyes,

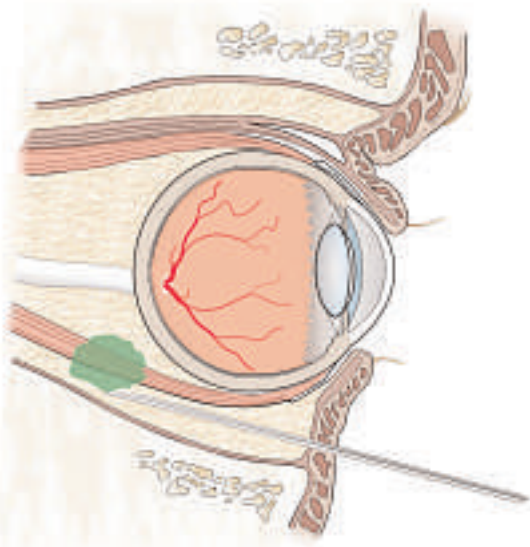


Figure 1:  
Orbital Floor Injection

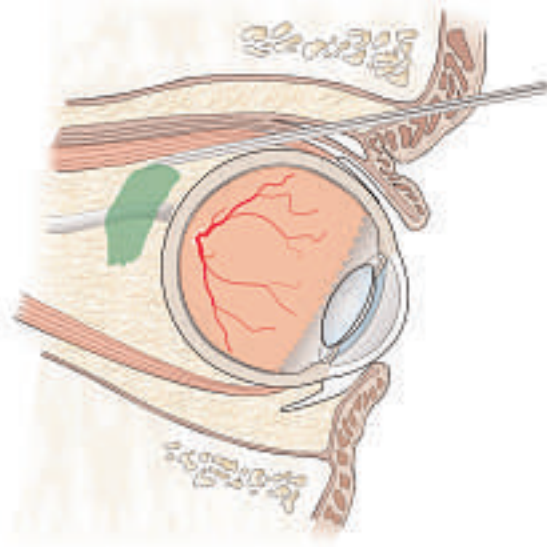


Figure 2:  
Posterior Sub-Tenon's Injection

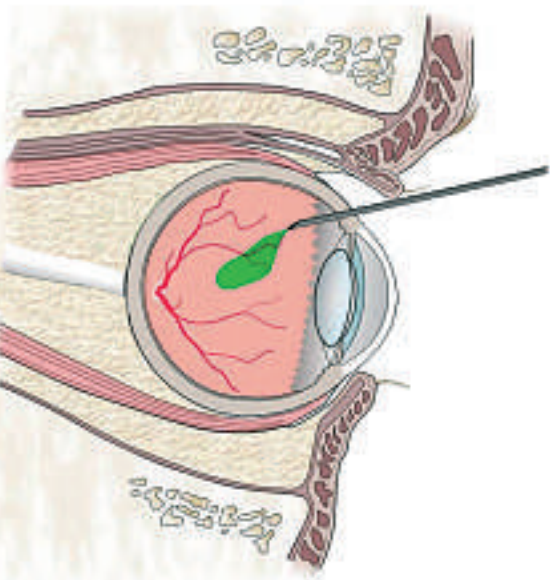


Figure 3:  
Intravitreal Injection

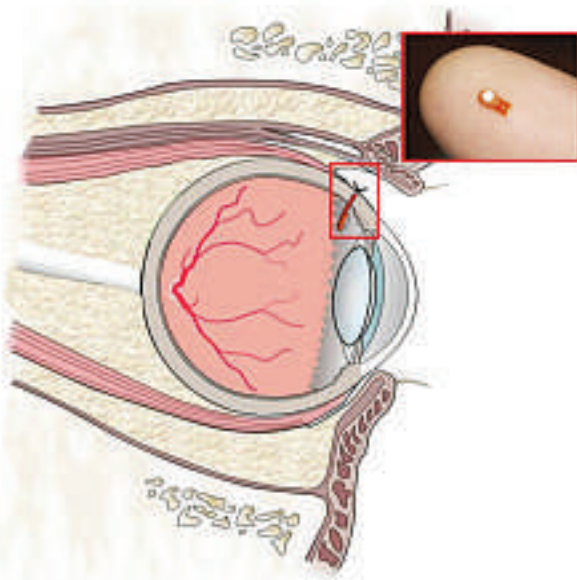


Figure 4:  
Implantation of a Steroid Device into  
the vitreous

but also, when other medical problems exist which contraindicate the use of oral treatment, such as poor controlled diabetes or high blood pressure, and also stomach ulcers or if severe

psychological problems like a psychosis had developed under the use of corticosteroids before. Local therapy with steroids should be avoided in uveitis caused by an infection and also if

you already have a problem with high pressure in your eye.

### **How are these Treatments given?**

The periocular injections are given under local anaesthesia and procedures can be carried out in the office environment. The intraocular injection needs a sterile environment (a separate room) and a well-defined standard procedure to minimize the risk of an infection. It is also given under local anaesthetic. The intraocular device is inserted in the operating theatre under local or general anaesthesia.

### **What happens after the Procedures, how long does the Effect last and what happens when the Effect is over?**

In any case the patient should be able to go home on the same day and you will be given a prescription for an antibiotic eye drop to be used for a few days. All other medications normally should be continued and the doctor will give instructions about how to start reducing them later. There should be a control appointment for a review visit in a short time.

For the injections, the duration of the effect depends on the type of steroid formulation used. There are some steroids which are considered long-

acting, while others are considered a depo (deposit). Both are used for periocular injections, but for intraocular injections the long-acting form (triamcinolone) is the one currently used. These formulations will allow duration of the effect of about 4 months. The implanted device uses a different steroid (fluocinolone acetonide) and has been designed to release the drug over a period of 2.5 years.

When the effect is over and the disease still active, which is the case in most patients, another injection, or a new device will be needed.

### **What happens when they don't work?**

Periocular injections may take a few weeks to become effective, but if they don't work after 4 weeks, the doctor will probably decide to repeat it. Only after a second or even third failure the procedure should be abandoned and other alternatives sought. Intraocular injections usually work very quickly (about 1 week) and if they fail it may indicate that the problem is very serious with permanent damage and no benefit in trying other forms of therapy may be expected.

Devices are implanted only after evidence of response to steroids is available, and they tend to work well for the full duration of the treatment (2.5 years). Relapses of the disease may still occur with the implant, but



they are much less common when comparing to oral therapy. If the device is not achieving the desired effect, and especially if it is causing problems (pressure rise), it can be removed.

## What are the potential Complications of these Treatments?

Some complications are related to the procedure (injection or implant) itself, while others will be due to the local effect of the steroid drug. During any injection or surgery complications can occur and they vary from simple ones such as haemorrhages, which may leave you with a black eye for a short time (in periocular injections), to more serious ones such as infections (in intraocular procedures), which, to mention the worst outcome, may result in loss of vision. Probably the most common complication for periocular injections is a droopy upper lid (ptosis). This tends to disappear within days of the injection, but rarely it may last longer or not reverse without surgery.

For the intraocular procedures there are also some long term potential problems, especially the appearance of cataract and elevation of the intraocular pressure.

Unfortunately after intraocular injections cataracts often progress and need surgery. The removing procedure

itself usually does not represent a problem, but may become a problem in young patients for whom a functioning clear lens is very important. High pressure may lead to glaucoma and the management involves eyedrops and sometimes surgery. It should be stressed that cataract and glaucoma are also not uncommon complications of uncontrolled uveitis.

It is also important to remember that even though the complications mentioned above may occur, the inflammation needs to be controlled or it will result in even more severe damage to the eye.

## Conclusion

Periocular, and more recently intraocular corticosteroids are very helpful ways to supply the uveitic eye with corticosteroids and to avoid major organic side effects, compared to systemic application. New types of corticosteroids are being developed which may be effective in the treatment of uveitis, but at the moment they are available only for undergoing studies and not commercially available. They will very likely represent new alternatives for the future.

# Side Effects of Corticosteroids

*The corticosteroid preparations used by the physician are modified derivatives of the natural glucocorticoid hormones produced in the body. Given the multitude of organ systems targeted by these hormones, widespread unwanted effects may be encountered with corticosteroid therapy. The severity of these side effects depends on the dose and duration of treatment. Ilknur Tugal-Tutkun, Professor for Ophthalmology at the University of Istanbul, Turkey, introduces the organs which can be affected during corticosteroid therapy in various ways.*

## Adrenal Suppression

High-dose long-term corticosteroid therapy inhibits production of native hormones. In cases of stress, such as major injury, infection, or surgery, the body's inability to rapidly produce adrenal corticosteroids may cause severe illness. Patients must inform any treating physician of their past or present corticosteroid therapy because corticosteroids should be reintroduced or the dose should be increased in acute stress. Too rapid tapering or sudden discontinuation of corticosteroids may result in a withdrawal syndrome characterized by symptoms, including malaise, muscle and joint pains, loss of appetite, and anxiety.

## Fluid Retention, Electrolyte Imbalance, and Hypertension

Fluid and sodium retention may cause edema, that is painless swelling of especially lower legs, ankles, and feet.

This side effect can be reduced by a low salt diet. A diet rich in potassium is recommended, in order to compensate for potassium loss. The blood pressure should be checked on a regular basis. Congestive heart failure may develop in patients who have an increased risk.

## Endocrine and metabolic Abnormalities

Redistribution of body fat results in a classical appearance called "Cushingoid state" which is characterized by moon face (puffing of face), buffalo hump (a lump of fat on the back of the neck), upper body obesity, and thinning of the arms and legs. Some individuals are more prone to develop this appearance than others. Serum lipids, both triglycerides and cholesterol, may be increased. Because weight gain can be enormous in some patients, a calory-controlled diet is recommended. This may also reduce the risk of developing diabetes.

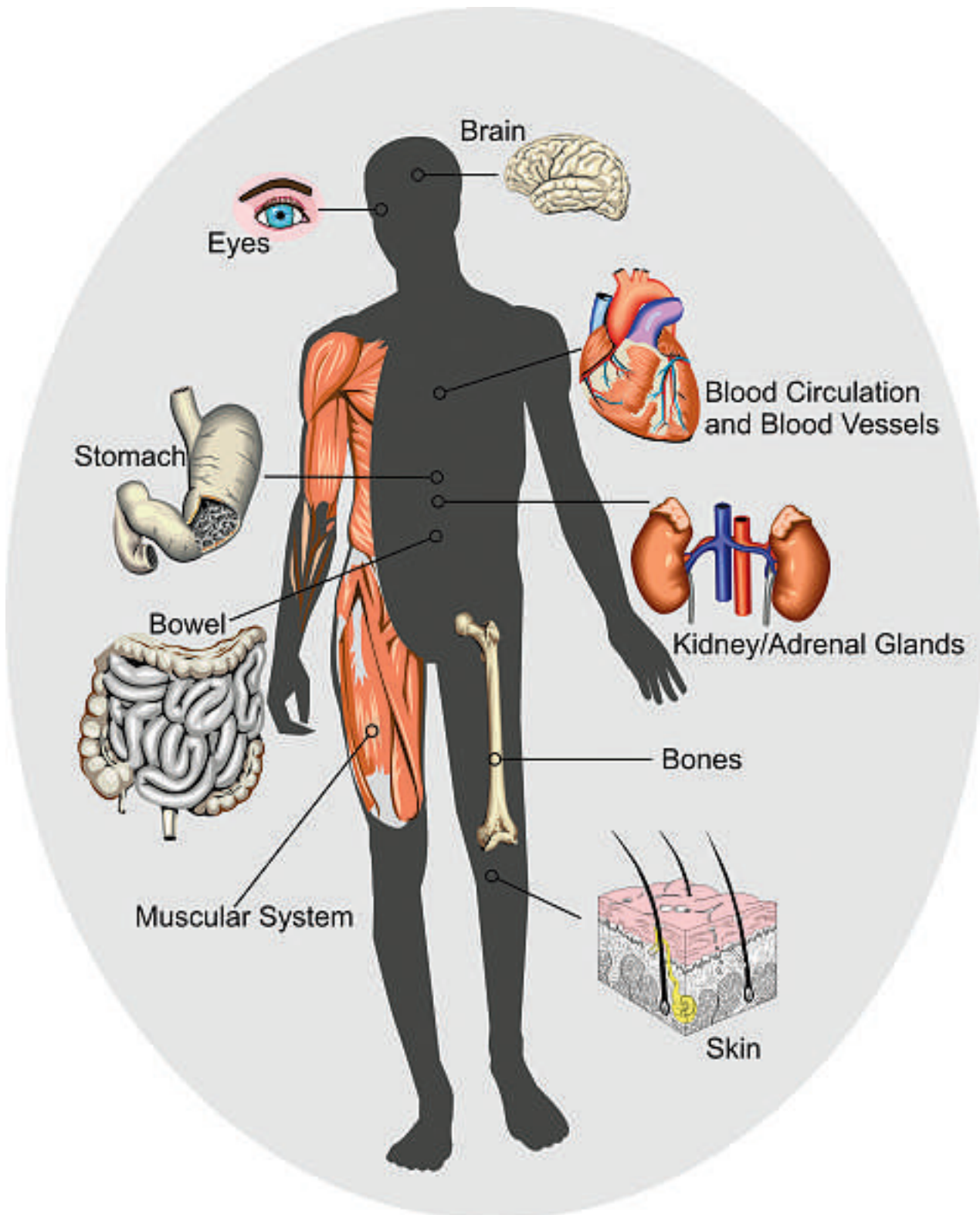


Figure:  
Various organs can become influenced under steroid-treatment

Corticosteroids can cause a change in glucose tolerance and an increase of blood glucose level by 10-20%. Increased thirst and frequent urination may be early symptoms. Diabetic patients must be aware that their blood glucose level, because it may deteriorate during corticosteroid therapy and that they may need an increased antidiabetic treatment. Sex hormones are reduced and menstrual irregularities and amenorrhea (stop of the monthly bleeding) can occur during corticosteroid therapy.

### **Gastrointestinal Disorders**

Gastrointestinal side effects of corticosteroids include increased appetite, indigestion, nausea, gastritis, stomach ulcer, bowel perforations, and rarely pancreatitis. A past history of peptic ulcer, smoking, alcohol consumption, and the use of other ulcerogenic drugs such as nonsteroidal anti-inflammatory agents are risk factors, and such patients require prophylactic treatment when corticosteroids are administered.

### **Osteoporosis**

Long-term corticosteroid therapy causes thinning of the bones and an increased risk of fractures. Elderly patients, postmenopausal women, smokers, and patients with limited mobility have an increased risk. Bone densitometry is an objective method of measuring bone mineral density and should be

performed at the initiation of corticosteroid therapy and annually thereafter, especially in the high-risk group. Calcium and vitamin D supplements may be recommended for prevention of bone loss. Anti-resorptive medications and hormones may be prescribed for the treatment of osteoporosis. Bisphosphonates are the only accepted prophylaxis for steroid-induced osteoporosis and should be used in all high-risk individuals from the beginning of therapy and for all other patients who develop osteopenia.

### **Osteonecrosis**

Also known as avascular or aseptic necrosis of the bones, this is a serious but rare complication of corticosteroid therapy. Head of the thigh bone (hip joint) is most frequently involved, but other large joints may also be affected. Joint pain and stiffness are the earliest symptoms. Early diagnosis is important in order to prevent further deterioration, because total joint replacement with prosthesis is the only definitive treatment when irreversible joint destruction develops.

### **Growth Retardation**

In children, corticosteroids inhibit long bone growth. Alternate day treatment may reduce this risk and discontinuation of corticosteroids may allow children to catch up their original growth rate.

## Myopathy

Muscle weakness and loss of bulk of especially the shoulder muscles and thighs can occur because of a reduction of protein synthesis. Potassium loss may also cause muscle weakness. Muscle cramps, pain, and weakness may limit mobility. Recovery of muscle weakness may be slow and incomplete even after discontinuation of corticosteroids.

## Neurological and psychiatric Disturbances

Onset of headache may be a symptom of increased intracranial pressure associated with corticosteroid therapy. Trouble in sleeping, mood swings, a false sense of well-being, excitement, restlessness, hallucinations, aggression, depression, and suicidal attempts may all occur even in individuals without any previous psychiatric problems. Patients and their families should be informed about these potential side effects when high-dose corticosteroid therapy is administered. Steroids are contraindicated in the presence of a psychiatric disturbance caused by previous exposure to the medication.

## Skin Changes

Increased sweating, darkening of skin color, facial rash, thin shiny skin, easy bruising, hair loss, hirsutism (unwanted hair growth), poor wound healing, acne, and stretch marks (reddish purple lines on arms, legs, and trunk) are the dermatological complications of corticosteroid therapy.

## Suppression of the immune System

Corticosteroid use is associated with an increased susceptibility to infections. Because severity of the infection may be masked, patients should seek medical attention even for mild symptoms that may suggest an infectious disease.

## Ocular side Effects

Long-term systemic corticosteroid therapy may cause cataract and glaucoma (optic nerve damage associated with increased intraocular pressure).

## Conclusion

Fortunately the most severe side effects are noticed only after long standing use of corticosteroids. It is mandatory to ask the patient, but also for the patient to inform the treating doctor about the side effects. Some of these effects can be avoided.

# Use of Corticosteroids in Children with Uveitis

*The probably most challenging group of uveitis patients are children who develop some of the most treatment resistant forms of uveitis. Even for them corticosteroids are the first choice of treatment. Prof. Arnd Heiligenhaus and Carsten Heinz, both working at the Uveitis Center of the St. Franziskus Hospital in Münster, Germany, summarize what is important to know about corticosteroids in children.*

## Endogenous Uveitis in Childhood

Uveitis in childhood is less common than in adults. It may appear in various infectious and non-infectious (endogenous) forms and is classified anatomically as anterior, intermediate, posterior and panuveitis. The most common form is anterior uveitis. Uveitis in childhood may be associated with a systemic immune-mediated disease, and the most important entities are juvenile idiopathic arthritis (JIA) and ankylosing spondylitis.

## Corticosteroids as first Choice Medication for Uveitis in Childhood

Independent of the patient age, the major goal in the treatment of uveitis is improvement or preservation of vision and protection from vision threatening complications. In the acute phase of the attack, a reduction of inflammation is

attempted. Thereafter, recurrence and chronic inflammation must be avoided.

Even in children, corticosteroids are the first choice medications for treatment. Profound clinical and experimental data show that they are highly effective to reduce inflammatory activity of uveitis. Favorably, the anti-inflammatory effect of corticosteroids begins soon after starting the treatment.

## General Remarks about Corticosteroid Use in Uveitis in Childhood

No general guidelines are provided for the use of corticosteroids, with the exception that the dosage of topical corticosteroids should be adjusted to the number of cells in the anterior chamber. Generally, complete abolition of any cells in the anterior chamber is attempted. Corticosteroid dosages, frequency and intervals of application

and length of therapy may differ markedly between the patients. The treatment regimen must be adjusted to the anatomic type and course of uveitis, the complications and associated systemic immune-mediated disease. The route of application, dosage and duration of corticosteroid application must be adapted to the individual course of uveitis.

### **Corticosteroids can be used by various Application Routes**

Corticosteroids may be used in various formulations. High dosages in the anterior chamber can be obtained with eye drops, gels or ointment. In childhood, eye drops are preferentially given during the day to avoid visual impairment and subsequent amblyopia. Dexamethasone 0.1% and prednisolone acetate 1% are favored due to their high anti-inflammatory potency. Ointment may be preferred at bedtime.

High dosages in the vitreous and posterior segment of the eye can be achieved by transseptal (located directly outside the eye ball) corticosteroid injections. Short-term preparations (dexamethasone) or long term preparations (triamcinolone acetonide) are available. In the presence of a high degree of inflammation, chronic cystoid macular edema (CME) or choroidal neo-

vascularization (CNV), corticosteroids (triamcinolone acetonide) may also be injected into the vitreous or anterior chamber. Due to poor compliance in children, injection may require a general anesthesia. No data are provided yet about the use of the recently introduced intravitreal inserts with corticosteroid depots (fluocinolone) in the treatment of uveitis in childhood.

High corticosteroid dosages in both the anterior and posterior eye segment can also be gained by systemic treatment. This can be achieved by the oral route, or by intramuscular or intravenous injection, the latter is named “bolus” therapy.

For anterior uveitis, steroids are commonly applied topically. For intermediate or posterior uveitis, steroids are preferentially given as injections or systemically. During the chronic course of disease, combined topical and systemic steroids, eventually combined with immunosuppressive drugs may be necessary.

### **Corticosteroid Use: Benefit versus Side Effects**

In many children, quiescence of inflammation can be achieved with corticosteroids in more or less high dosages. While long-term remission is intended with continued dosages, there

is a considerable risk of untoward side effects. The critical threshold between benefit and side effect is not well defined.

As in adults, the major side effects from topical application are cataract formation and glaucoma. The rate of cataract induction increases in a dose dependent manner. The typical systemic side effect is Cushing disease. Characteristic symptoms vary, but include obesity, rounded face, slowed growth rates, thinning and stretch marks of the skin, weakened bones, fatigue, weak muscles, high blood pressure, high blood sugar, irritability, anxiety, depression, excess hair growth and irregular menstrual periods. Frequent application of eye drops or repeated transseptal injections may also lead to systemic side effects. The critical corticosteroid dosage that may be safe is not well defined. The higher anti-inflammatory potency and dosage are the more side effects can be found. For the long-term use, eye drops should be given  $\leq 3$  times daily and oral prednisone should be used at dosages less than 0.1 mg / kg bodyweight daily.

In patients with ocular hypertension, rimexolone 1% may be preferred as eye drops, as it has a lower risk to raise the intraocular pressure. Fluorometholone formulations may be preferred as a long-term maintenance treatment in

patients with low-grade anterior uveitis, as it has a lower risk for cataract formation. As dexamethasone is a phosphate-buffered solution, it may not be used in patients with high risk for development of band-keratopathy, e.g. in anterior uveitis in JIA patients.

### Recurrent acute Anterior Uveitis

Treatment should be instituted as soon as possible after the patient experiences the typical signs for acute uveitis. Corticosteroids are started at high dosages, e.g. every 30 to 60 minutes, and are tapered off slowly. Highly potent corticosteroid formulations are preferred initially (prednisolone acetate 1%, dexamethasone 0.1%). If disease is very severe, additional regional injections, preferably of short-term corticosteroids (dexamethasone) are given in children that may tolerate the injection. Commonly, systemic corticosteroids are added with a tapering within several weeks. In this type of uveitis, systemic non-steroidal immunosuppression is rarely necessary.

### Iridocyclitis in juvenile idiopathic Arthritis

Uveitis is common in oligoarthritis (inflammation of a few joints *Figure 1*) and RF(rheumatic factor)-negative polyarthritis (inflammation of multiple joints). Up to 25% of the patients suffer from chronic anterior uveitis.



It is important to know that the inflamed eyes generally appear as a white globe (Figure 2). As visual loss is frequent, an aggressive treatment may be required.

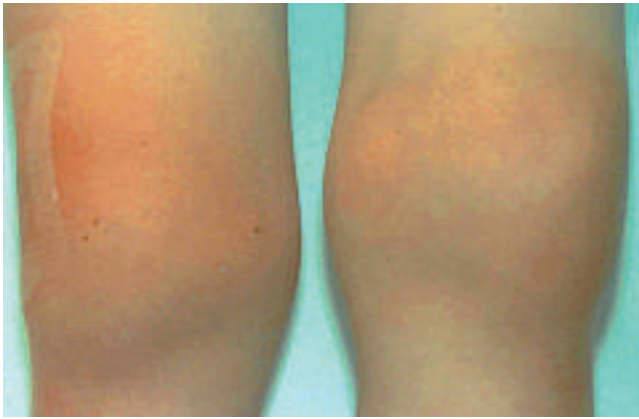


Figure 1: Oligoarthritis of the knee in juvenile idiopathic arthritis, often associated with anterior uveitis in children.

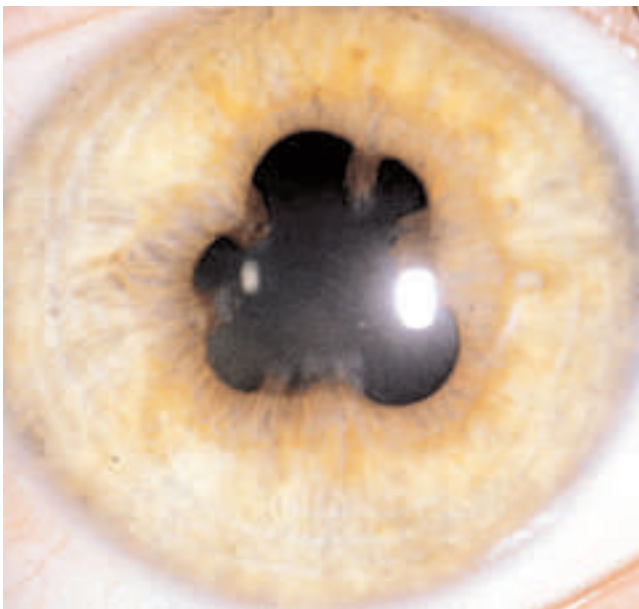


Figure 2: This "white eye" seems without inflammation, but it has massive cells in the anterior chamber.

A complete abolition of any cell in the anterior chamber must be obtained. A step-ladder approach has been suggested. In general, treatment is initiated with a trial of prednisolone-acetate 1% at high dosages. When inflammation is under control (means: no cell in the anterior chamber), the topical corticosteroids are tapered down slowly within several weeks. If complete quiescence is obtained with 3 drops or less daily, this may be continued. The dosages are subsequently reduced to the lowest possible level, and replacement with a less potent formulation (rimexolone, fluorometholone) may be preferred. Topical non-steroidal anti-inflammatory drugs alone do not appear to be effective to obtain or maintain quiescence of inflammation. Transseptal corticosteroid injections may be given in selected cases (children old enough to tolerate injection; otherwise under general anesthesia), e.g. with hypotony or macular edema.

Due to the untoward side effects and lack of efficacy, long-term use of systemic corticosteroids is not suggested. When long-term quiescence cannot be achieved with low-dose corticosteroids, immunosuppression is indicated even in the absence of vision threatening complications or visual loss.

### Pars planitis and intermediate Uveitis

Pars planitis (intermediate uveitis)

without associated systemic disease) is quite common in childhood. It involves vitreous, ciliary body and peripheral retinal vessels. Deterioration of vision may arise from vitreous opacity, CME, cataract formation or epiretinal membrane formation. Pars planitis may be a severe disease with the risk of visual loss that needs to be treated aggressively. Corticosteroid eye drops are not helpful. Although regional corticosteroid injections (triamcinolone) through the lower lid may be preferred, this may not be possible in childhood without general anesthesia. Therefore, oral corticosteroids are commonly given. However, immunosuppression (e.g. methotrexate or cyclosporine A) may be indicated in patients not responding properly or in order to reduce the systemic corticosteroid dosage, to prevent side effects, e.g. cataract formation.

### **Treatment of uveitic Complications with Corticosteroids**

Corticosteroids are of particular importance for the treatment of CME (see [uveitis](#) 1-2005). It has been repeatedly shown that improvement of vision in uveitis patients can be obtained with corticosteroids. Previous studies have suggested that transseptal corticosteroids have a positive influence on inflammatory activity, vision and CME. This has also been demonstrated for

oral, intravenous and deep intramuscular routes. Several studies have shown that CME in uveitis patients may completely resolve after an intravitreal injection of triamcinolone acetonide. However, improvement was transient in many of the patients.

### **Conclusion**

As true in adults, corticosteroids are also the first line of drugs for uveitis in children. Side effects may be profound, such as cataract formation, and difficult to be diagnosed (elevation of intraocular pressure, depression). Recently it has been shown that corticosteroids, and especially in the therapy for anterior uveitis associated with juvenile idiopathic arthritis, should not be given excessively long or at high dosages, that they may be substituted by immunosuppressive drugs quite early.

# Thoughts about Steroid Treatment for Uveitis

*There is a huge amount of different opinion and information available now about steroids, regarding both their advantages and disadvantages. Often it is difficult for patients to recognise what is important and what to be aware of when they are supposed to start steroid treatment. Unfortunately, patients will hear a lot of different opinions about steroids, depending on who they are talking to. It would make the cooperation between all the involved parties much easier if they understood steroids better. Here, we summarized the response of an Ophthalmologist, an ophthalmic nurse, who has a lot of experience with uveitis patients, and finally of a patient. We want to see their different viewpoints, according to the question: "What are the most important things about steroids?"*

## From the Standpoint of an Ophthalmic Nurse

Zania McKenzie is a nurse with a specific remit to work with uveitis patients in a uveitis clinic in Edinburgh in the United Kingdom.

### ■ Professional Relationship between Patient, Nurse and Doctor

For a patient to gain the maximum benefit from treatment with steroids, it is essential to build a trusting professional relationship with the doctor/nurse. The patient - nurse - doctor "team" should feel comfortable enough to discuss any aspect of concern, and treatment compliance,

because corticosteroid treatment has such individual requirements and diverse considerations regarding quality of life, including general health, fitness, diet and lifestyle.

I really do feel that the dosage, benefits, risks, compliance etc. should be privately and sensitively, also honestly discussed with patients. If the realities of steroids are "bluntly" listed in public print, then I think more problems could arise with lack of trust and refusal to take them. Non compliance with steroid treatment can lead to a serious risk of patients permanently losing their sight.

If patients are taking any medicines including steroids for any reason or condition (other than uveitis), they must discuss these with their doctor / nurse so that they can make sure that they do not react adversely with uveitis treatment.

### ■ Common Misconceptions with Steroids

Patient's misconceptions about steroids need to be identified regarding informed consent to treatment and ongoing compliance.

Anabolic steroids have received increased public awareness through body building drugs that “mimic” the male hormone Testosterone. These are sometimes prescribed by a doctor if natural male development doesn't occur. Unfortunately they are sometimes illegally obtained to enhance competitive sports performance and carry long term health risks. They would never be prescribed for the treatment of uveitis.

Female gonadotrophic hormones are steroids that have received increased public awareness through infertility treatment for women. They are not prescribed for treatment of uveitis.

## From the Standpoint of an Ophthalmologist

**John Olson is a Consultant Ophthalmic Physician at the Aberdeen Royal Infirmary in Scotland**

### ■ Efficiency

It is vital to both doctor and patient that the corticosteroids work, not only that they work but they should work very quickly. When sight is affected there is naturally concern that it has been lost for good. The rapid recovery that occurs with steroids brings hope, optimism and confidence to the relationship between doctor and patient. This is important as for a significant few treatment is going to be prolonged with various challenges along the way.

### ■ Is the Diagnosis correct?

If they do not work quickly then this is a red flag to the doctor indicating that perhaps this is not inflammation on its own. Infection is a rare cause of inflammation in the eye, but can often be cured or at least aided by antibiotics or other anti-infective treatments. Infection is not always easy to identify as taking a sample of the eye risks affecting its very function. This red flag is therefore a very important signal telling the doctor to think again.

## ■ How to handle the Steroid-Treatment

Steroids do not come without cost. In the first few days of treatment patients often notice an effect on their mood. Usually they feel more cheerful and more energetic. The downside is that they often find it very difficult to sleep at night. If you are prone to a low mood this occasionally is worsened and very rarely patients hallucinate. Within the first few weeks of taking steroids, particularly if large doses are given through a drip, then patients may notice their “teenage acne” returning. Thankfully steroid acne usually spares the face and affects the chest. Both these side effects resolve on reducing the dose. It is important, however, not to make any important or life-changing decisions whilst on high dose steroids as you may not be thinking exactly as you would do normally.

After the relief of their sight improving patients and doctors then start to focus more on the long-term side effects of steroids. One of these problems starts if you stop your steroid tablets too quickly. The usual reasons patients give me are “my prescription ran out and I thought I would wait to see you again” or “I stopped taking them because they made me feel miserable”. Steroids are strange beasts. Usually if a tablet makes you

feel unwell then the advice is to stop taking it. With steroids you must never do this without seeking medical advice first. Why is this?

Our own body normally makes the equivalent of about 7.5mg of prednisolone a day. Your own steroids help you keep your blood pressure at the right level and also help you fight the “stress” infection puts on the body. When you have an infection your body will normally make twice as much steroid to cope. If you have too little steroid “on board” and an infection hits then your blood pressure drops, you feel awful, you may black out and you may become unconscious. As well as this you often develop diarrhoea. In this situation you must get more steroids on board immediately. If you have diarrhoea, steroid tablets will often be ineffective as they just pass through and you may well need an injection. It is difficult to be precise but your steroid card should tell you how much to increase your medication by and you must seek urgent medical help.

## ■ Why doesn't the Body realise this and just make more Steroids?

If you take steroid tablets, the pituitary gland detects this in the blood, which floats past it at the base of the brain. It is

the “conductor” of the endocrine “orchestra”. Normally it sends a message to the adrenal glands on top of your kidneys telling it how much steroid to make. The dose of prednisolone you will have been given to start with is far higher than the body would produce. The pituitary gland detects this, stops sending any more messages to the adrenal glands and basically goes on holiday. Unfortunately if you stop taking steroids too quickly the pituitary doesn’t bother rushing back from its holiday. It can take months before it starts working properly. The bottom line is: do not stop taking your steroid tablets without medical advice.

## ■ How to handle Side Effects

A while after starting steroids, often when the dose of steroids is quite small, patients may start to notice that their face may be round and that they have put on fat on their abdomen but not their legs. This is the cushingoid appearance that used to mark out many people on steroids. As long as the prednisolone is kept in single figures it will go with time. If the steroid dose is kept high and the weight gain persists then there is a risk that diabetes will occur. Normally a hormone called insulin, which is made in the pancreas, tells the body to pick up the food it needs from the blood stream. If your body becomes “too big” there is not enough

insulin to go round and you leave food behind. Also if you have too much fat your own insulin seems to work less well. This leads to high sugar levels, which damage your blood vessels making you at risk of heart attacks, strokes, kidney disease and problems with eyesight, if it is not managed properly. As the mainstay of treatment for diabetes is controlling what you eat, this can be quite difficult.

Steroids also cause the body to retain salt. This increased salt level, particularly in the blood, drags water with it raising the pressure within the blood vessels. This can cause your ankles to swell and cause hypertension, another cause of damaged blood vessels. This can easily be managed with tablets but the best approach is to reduce the dose of steroids.

Steroid tablets can also cause weakening of the bones (osteoporosis). This is completely painless unless the bone crumbles or breaks. The bones most commonly affected are the back and the hip. If the bones in the back are broken this can cause a lot of pain. The patient will lose height and if more than one bone is affected the patient can become stooped with the head falling forward. This is much like the figures seen on road signs to indicate the presence of elderly people. Taking preventative medication once a week, walking

regularly, avoiding cigarettes and not drinking too much alcohol can largely prevent all this. As it is related to the total amount of steroid you have consumed, amongst other things, it is another reason why doctors are keen to use other treatments as well as steroids.

## ■ Why do we use Steroids if they are so dangerous in the long Run?

Steroids work very quickly and most of our other treatments take a long time to work. It is a bit like shutting an overfull suitcase. The steroids are the big weight to enable you to close the lid. Once the lid is closed then the latches can be used to keep it shut. Trying to shut the lid by pulling the latches together is largely ineffective. So what do we do? We use steroids to get control and if you need more than a small amount to keep the inflammation away we encourage you to use other drugs as well. It is better to use small amounts of a few drugs than large amounts of only one drug, as the risk of side effects is usually far less.

## ■ Conclusion

All this sounds a bit doom and gloom. However, this is why we need specialist doctors trained in uveitis. With experience and careful use of drugs, these uveitis specialists will enable many patients to retain their sight, free from significant side effects.

## From the Standpoint of an Uveitis Patient from the UK

**CR:** a patient with posterior uveitis

### ■ About the Fear of Side Effects

As a healthy person who had discovered in the 'prime of life' I had an eye condition which was going to need treatment with steroid drugs, the first thing I remember was having a natural aversion to taking drugs in general. It is something some of us seem to be conditioned with, even being reluctant to take paracetamol for a headache.

Steroids seemed to be such a familiar term and it is impossible to think of steroids without thinking of visions of banned athletes, although it doesn't take long to realise that corticosteroids are completely different. The next thing to come to mind about steroids is that they just don't sound like a good thing, - they seem to have a bad reputation. Don't they have side effects, putting on lots of weight, or getting a funny shaped face?

At first, you realise you have views about taking steroids long before you have considered any proper facts about them. The next step was to find out about them. The internet definitely comes to mind when looking for medical information but "Google" comes up with millions of results for

steroids (nearly 19 million actually). Next there are patient information leaflets that come with the drugs and these list an extraordinary number of side effects, most of which seem to appear on every type of drug information you read.

The thing I couldn't work out is whether I was going to suffer all, some or none of these side effects. What were the chances of suffering the side effects, compared to catching a cold or being run over by a bus?

I eventually decided that I couldn't really decide just how bad or not the side effects would be and so I felt I needed to speak to someone to get a realistic idea of what to expect.

I think this is where being able to speak to someone at the clinic or being able to speak to someone from a patient support group is the best way to know what to expect.

In the end the side effects that most affected me were the 'psychological' ones. Changes in mood and feeling tired unpredictably were harder to deal with than the physical side effects which I found didn't really affect me much.



# Steroids in Uveitis: Patient Reports

## Patient Report from Germany

Before 1996 until the treatment with Steroids there was a permanent worsening of my visual acuity which was due to a rare form of posterior uveitis, the so called Birdshot Chorioretinopathy. By estimation, this is seen in Germany in less than 100 persons. Because of inflammation of retinal vessels, both eyes developed vitreous inflammation and massive oedema of the macula. The regular ability to read soon was gone: Night blindness, vision through a tunnel, looking like through a fog, and reduced vision of colours were characteristic for my vision.

Because my disorder is a posterior uveitis only steroid tablets seem to be effective, because topical steroids will not reach the retina in adequate dosage. Normally one starts the treatment with high dosages at the beginning. After this, the dosage will be reduced in multiple steps until the steroids were stopped.

My first treatment course started with 75 mg of prednisolone per day and induced a nearly prompt improvement of my disease. After five steps of reduction I had reached 20 mg of steroids and this was when worsening occurred. After three months with 5 mg this treatment was stopped and a second course was started with 50 mg of steroids, which finally ended with 2.5 mg. Again we found steroids very effective for my disorder, but only in high and medium dosages.

In both courses I had observed that on the one hand the side effects were more when the dosage was high, on the other hand my body was very irritated when I had reached the low dosages. In times with high dosages I had sleeping problems, reduced weight, had an euphoric affect, “doping-like” increase of my power, muscular cramps and diarrhoea. In case of heavy reduction of the steroids, I realised exhaustion, listlessness, sleeping problems, melancholy and problems with my circulation. But I never realized other often described symptoms like

# Patient

weight gain, a moonface or elevation of blood pressure, although I have taken steroids for nearly 4 years. Evidently there is an individual component playing a major role for these side effects.

I had noted that the rate of reduction of steroids affected some changes of the reaction of my body. In the hope to find a relation between a high percentage reduction of steroids and the problems of my body, I counted the percentage of changes for each step of steroid reduction. In some steps I really was able to see such a connection. Of course, using a few observations, this connection is not a proof from a statistical side. Despite that I did not have any other ideas, so I started from the working hypothesis that from a certain percentage of steroid reduction the body becomes irritated and the danger of a uveitis recurrence may exist. For all steps of reduction, I have chosen the same percentage value and fixed that relatively low on 15 percent, to reduce the risk of a recurrence as low as possible.

This third course of steroid treatment had been started with 60 mg per day. With the slow reduction rate of 15 percent, multiple steps were needed until the steroids were stopped. On average after 5 days the dosage was reduced until 10 mg, to limit the whole

time of steroid treatment even more. After this I choose time periods of three to four weeks.

To reduce the danger of unrealized worsening of the macular edema, I used the well-known Amsler Grid. Additionally I established my daily reading test: I prepared the sentence "This is a test" in different large letters on one sheet of paper and I used to read this sentence separately with both eyes having the goal in mind, that with reduced visual acuity I would not reduce the steroid dosage anymore. Later on I also transferred such a reading test into the distance: I prepared a poster and tried to read the letters in various meters of distance.

For counting the results of this steroid course correctly I also have to mention that in addition to steroids I partly had taken mycophenolate mofetil, cyclosporin A and interferon, drugs which definitely may have covered the reaction of steroids. But I can report, that following my observation the extreme strong reaction, which was found in the first and second course of massive steroid reduction, was not seen in this third course using 15 percent reduction rate of steroids. Until reaching a dosage of 2.5 mg of steroids – without treatment of interferon – there was no recurrence. The uveitis was burned out; but I realized a therapy resistant macular oedema, which finally resolved after a few days with interferon treatment.

How long will it take until a reduced visual acuity (after a recurrence) responds to higher steroid dosages? In my case the steroid dosage was elevated from 2.5 to 15 mg after such a recurrence. With my visual test, mentioned above, I realized that my bad eye needed 25 days and my good eye 15 days to reach my old visual acuity.

**Jürgen Freytag**

## Patient Report from Italy

Since 2004, uveitis entered my life and nothing has been the same. Previously I had never known even the name. I thought that maybe the stress was the trigger for this disease, and I was scared about the possible side effects of the suggested steroid treatment. My red eyes, so sensitive to light, my blurred vision, were terrible elements that have changed my life.

The first doctor I met, said that the best approach would be dexamethasone eye drops 6 times a day for one week and then decrease the dose gradually; apparently it worked: my eyes became white and the pain disappeared. One week after the end of the treatment there was a violent relapse. The doctor that gave me the first care said that the treatment I had done was effective and suggested to repeat it, but this time it

was not effective: I decided to call another doctor.

I was admitted to the hospital, examined for several blood tests, x-rays, and many more procedures. Fortunately, nothing was wrong. At the same time I received 3 injections “near” my right eye (he called them “sub-tenon injections”) and I recovered my sight, without any side effects, continuing to put steroids eye drops in both eyes. I supposed to have reached the end of my nightmare.

I was not right.

So, another doctor tried to help me repeating the same treatment: another doctor, same therapy, same failed result. Nothing changed and somebody said that in another center in Italy I would find the answer for my personal tragedy.

The “new” doctor said that I had an condition called “Behçet’s Disease”, telling that the anterior uveitis was not so aggressive and the best option would be...topical eye drops! It is easy to understand that the result was not so impressive.

Another relapse, another travel, another doctor, same therapy. But that time, the last doctor, who thought that the diagnosis I had received was not right, referred me to a “tertiary referral center”, where I have met a doctor, my

# Patient

doctor, probably the only one that really knows about uveitis.

My sight was particularly affected in the left eye because of a complication called “cystoid macular edema”, possibly generated by the long action of the ocular inflammation. He said: “It is necessary to change the strategy: you have never used systemic steroids and they are necessary to stop the long-standing inflammation, but you have to carry the temporary side effects. This will be not simple, but you have to fight and win. Oral prednisone should help you.”

The summary of that strategy was: no more topical, but systemic steroids. I had no severe problems with temporary side effects due to systemic steroids, and after 2 months my sight recovered almost completely, but a small amount of cystoid macular edema persisted and we decided to have a sub-tenon injection of tramcinolone (another different steroid) to control the inflammation better. My sight totally recovered, but another “enemy” was ready to fight against me and my eyes: raised intraocular pressure. I felt fear.

The fight was long and hard: for a long time I put in my eyes anti-glaucoma drops to control the high pressure, but

even taking acetazolamide orally, the raised pressure was not under control. The doctor decided to remove the steroid in my scleral tissue, thinking about the possibility to do also a surgical procedure called “trabeculectomy” if that operation would be not effective. But it was: 2 weeks after removing my steroid depot, my pressure was completely normal.

Now, I’m on a low dose of systemic steroids, my eyes’ pressure is normal, my sight is quite good, and I’m fine: for the first time I’m feeling “normal”. I have got an opinion: steroids have several possible side effects, but if you know them, you should not fear them; so, you don’t need only steroids, you need a doctor able to look into your eyes like a friend, able to give the strength to fight, a sort of “special guide”: the last doctor, my doctor, did it.

**Pietro Baldassarre**

---

# Physicians and Uveitis

## News from the Scientific World

### The Uveitis Awards from the German Uveitis Patients Interest Group (DUAG) 2005

Since 2003 the **DUAG** has supported uveitis research by donating awards to clinical and experimental uveitis research. One of the main goals within the constitution of the **DUAG** is to achieve “support of scientific research”. In September 2005 the awards were presented during the congress of the SOE (European Ophthalmology Society) in Berlin, Germany. In the experimental field there were two first awards, and in the clinical field two second awards. Here, the winners presented their award winning articles to the congress audience. Our readers will find a summary on the following pages. **Prof. Manfred Zierhut**, the President of the **DUAG**, describes the process to select the winners and the topics of the winning papers. As in previous years, **Bausch & Lomb Co.**, Rochester, USA, sponsored the awards. We would like to thank this company very much for their support!

#### How the Winners were selected

As in the previous year there were two award categories, one in the field of experimental and one in clinical uveitis research. A team of 6 experts had to choose the best 3 publications in each field, published in the scientific literature of the year 2004. “Scientific Literature” relates to journals where articles undergo peer review (means likely to be important and new). This secures a high grade of quality in itself. The money award goes to the first author, the document of honour to the whole group.

In the first round, each expert had been asked to nominate what he or she

thought were the best 4 articles. This resulted in a list of 13 clinical and 12 experimental articles. In the final round each expert had to give points to four of these nominated papers (5, 10, 20 and 30). In July (for the experimental awards) and in August (for the clinical awards) the winners were notified. Because no other uveitis awards exist, the winners were very happy.

#### What was the Content of the winning Articles?

Until today the mechanisms leading to uveitis are not well known. Most of the experimental work today is currently undertaken in animal experiments. There are models of uveitis in mice

# Physicians and Uveitis

and rats which are very important since they very closely mimic the human uveitis. The first article (Smith and co-workers) investigates a major cause of posterior uveitis, induced by the parasite *Toxoplasma gondii*, and why this preferentially induces retinal disease. The second article (Xu and co-workers) reports about experiments which are designed to find out how inflammatory cells find the eye as their destination, leading to uveitis. The third article (de Kozak and co-workers) reports on improvement of treatment by using very small particles, called nanoparticles.

The clinical articles reported on two well known uveitis types, the final one about investigations to analyse the role of white blood cells and why they are so active in uveitis inflammation. The first report (Rothova and co-workers) dealt with the prognosis of the so-called Birdshot-uveitis, a posterior uveitis which is characterized by a typical clinical pattern. The second paper (Tugal-Tutkun and co-workers) studied a huge population of Turkish patients with the so-called Behçet's uveitis, a multiorgan disorder. The third article (Curnow and co-workers) investigates lymphocytes (white blood cells) and their role in the anterior chamber during a uveitis.

## Why do we need Uveitis Awards?

The **DUAG** awards are still the only uveitis awards. This is even more special because they are donated in the name of an ocular disease patient interest group. We plan to establish the awards as a qualification criterion in the coming years so as to help the winners in their careers giving them a better chance of obtaining research grants and thereby expanding research into uveitis.

As in previous years, the Award Committee and the **DUAG** agreed that all six awarded publications offer an important new aspect in the management of clinical uveitis or improve our knowledge regarding the mechanisms playing key roles in experimental uveitis, therefore probably delivering ideas for new therapeutic targets. Making new scientific results more easily and quickly available to ophthalmologists, and also to health insurances, is a major goal for patient interest groups in all countries. This will ensure a modern and more successful approach to diagnosis and therapy for uveitis-patients.

# Physicians and Uveitis

## The experimental Uveitis - Awards

### 1<sup>st</sup> award

Smith JR, Franc DT, Carter NS, Zamora D, Planck SR, Rosenbaum JT.

### Susceptibility of retinal vascular endothelium to infection with *Toxoplasma gondii* tachyzoites.

Published in: Investigative Ophthalmology & Visual Science 2004; 45: 1157-1161.

This paper describes our investigation of the interaction between *Toxoplasma gondii* (*T. gondii*) and endothelial cells (cells that line the blood vessels) of the retina. Toxoplasmic retinochoroiditis, the commonest form of retinal infection worldwide, has been the subject of the edition of *uveitis* (2/2005). The *T. gondii* parasite may be contracted by eating undercooked meat or by ingesting material that is contaminated with cat feces. It may also be passed from an infected pregnant mother to her unborn child. After entering the body, the parasite prefers to lodge in the retina and brain than other organs. The reason for this preferential localization is unknown. One possibility is that the eye and brain do not fight infection as vigorously as elsewhere in the body. Another possibility is that the parasite penetrates these tissues more easily than other organs. To enter the retina, *T. gondii* must cross the retinal endothelial cells (the inner cell layer of retinal vessels). We hypothesized that retinal endothelium was more susceptible to infection with *T. gondii* than other endothelium.

To test our hypothesis we measured the susceptibility of different endothelial cells to *T. gondii* infection using a method called the [<sup>3</sup>H]-uracil incorporation test. In these experiments, cells from a human being are grown in a dish. When cells completely fill the dish, they are infected with *T. gondii*. A chemical called uracil - that is joined to a radioactive label, [<sup>3</sup>H] - is added to the dish; *T. gondii* parasites need uracil as they grow inside the cells. One day later the amount of radioactivity ([<sup>3</sup>H]-uracil) in the dish is measured. The measurement indicates how well *T. gondii* grew inside the cells in the dish. If the radioactivity is high (ie, *T. gondii* incorporated lots of [<sup>3</sup>H]-uracil), *T. gondii* grows well in the cells. In other words, if the radioactivity is high, the cells are very susceptible to infection with *T. gondii* parasites.

# Physicians and Uveitis

We compared retinal endothelium with endothelium from other parts of the body, including the aorta (which is the large vessel that runs through the chest and abdomen), the placenta and the skin. We observed that retinal endothelium yielded the highest radioactivity readings of all cell types tested. From this work we were able to conclude that cells lining the blood vessels of the retina were more susceptible to *T. gondii* infection than cells of blood vessels elsewhere in the body. This may explain, at least in part, why *T. gondii* infects the eye rather than other body organs. Presently we are focusing our research on understanding what causes this susceptibility to infection. It may relate to: strong attachment between *T. gondii* and the retinal endothelial cell; fast division of *T. gondii* within the endothelium; and/or chemicals produced by the infected cells that help *T. gondii* to grow.



*Fig.: 1st experimental Award – from the left to the right side: Justine Smith (Portland), Matthias Becker (Heidelberg / DUAG)*



# Physicians and Uveitis

## 1<sup>st</sup> award

Xu H, Manivannan A, Jiang HR, Liversidge J, Sharp PF, Forrester JV, Crane IJ.

**Recruitment of IFN-gamma-producing (Th1-like) cells into the inflamed retina in vivo is preferentially regulated by P-selectin glycoprotein ligand 1: P/E-selectin interactions.**

Published in: Journal of Immunology 2004; 172: 3215-3224.


The main concern for uveitis patients is to get the inflammation under control promptly and effectively. Although treatment of uveitis has improved over the last decades, current therapies are non-specific and associated with major side effects. Alternative therapies with more specific anti-inflammatory effects and fewer side effects are therefore urgently needed. During inflammation, inflammatory lymphocytes (white blood cells) are constantly recruited from the blood vessels into the inflamed tissue. Preventing the recruitment of inflammatory cells should therefore effectively control inflammation.

The first step of inflammation of the eye starts, when lymphocytes, the so-called adhesion molecules and structures of the eye like retinal blood vessels interact. Adhesion molecules are proteins, which interact between lymphocytes and the vessel, resulting in an uptake of the inflammatory cell into the eye. Always two adhesion molecules (one on the lymphocyte, one on the vessel) interact. Our study aimed to understand the mechanism that controls migration of inflammatory cells from retinal blood vessels into inflammatory retinal tissue. Experiments were carried out in mice with experimental autoimmune uveoretinitis (EAU), an animal model for human uveitis. CD4<sup>+</sup> T cells, one subset of the white blood cells, are believed to play important roles in the development of uveitis. Three types of CD4 T cells namely naïve CD4 T cells; IFN-gamma-producing (Th1-like) CD4 T cells and non-IFN-gamma-producing (Th2-like) CD4 T cells were labeled with fluorescent dye and then transferred into mice with uveitis (EAU). Movement of the labeled cells in the inflamed retina was recorded digitally using a cell tracker system called scanning laser ophthalmoscope (SLO). We found that more Th1-like CD4 T cells rolled in the inflamed retinal vessels and later migrated into inflamed retinal tissue as compared to naïve CD4 T cells and Th2-like CD4 T cells. Further mechanism study revealed that adhesion molecules such as P-selectin glycoprotein ligand 1 (PSGL-1) and LFA-1 were expressed at higher levels on

# Physicians and Uveitis

Th1-like cells, whereas another adhesion molecule, CD44 expressed higher on Th2-like cells. In the inflamed retina P-selectin, E-selectin, and ICAM-1 were up-regulated on the vessel segments with inflammation. Th1-like cells were not able to infiltrate the eye, when the interaction of PSGL1 on Th1-like CD4 T cells and P/E-selectin on inflamed retinal vessels with an antibody against PSGL1 was blocked. On the other side, anti-LFA-1 antibody which blocks LFA1 on inflammatory cells, and ICAM-1 on retinal vessels and anti-CD44 antibody which blocks CD44 on T cells and hyaluronic acid on retinal vessels inhibited the infiltration of both Th1- and Th2-like cells.

Our data suggest that random movement of activated CD4 T cells (both Th1- and Th2-like CD4 T cells) across the retinal blood vessels is mediated by the adhesion molecule pair CD44:CD44 receptor and LFA-1:ICAM-1 interactions. Preferential recruitment of Th1-like cells, especially important for the initiation of uveitis, is mediated by PSGL-1:P/E-selectin interaction. Treatment designed to block the interaction between inflammatory cells and blood vessel wall such as PSGL-1:P/E-selectin interaction in uveitis could prevent inflammatory cell infiltration and therefore effectively control the inflammation.



*Fig.: 1st experimental Award – from the left to the right side: Hans-Jürgen Werndt (Bausch & Lomb), Heping Xu (Aberdeen, UK), Silke Greif (Essen / DUAG), Manfred Zierhut (Tübingen, / DUAG)*

# Physicians and Uveitis

**3<sup>rd</sup> award**

de Kozak Y, Andrieux K, Villarroya H, Klein C, Thillaye-Goldenberg B, Naud M-C, Garcia E, Couvreur P.

**Intraocular injection of tamoxifen-loaded nanoparticles: a new treatment of experimental autoimmune uveoretinitis.**


Published in: *European Journal of Immunology* 2004; 34: 3702-3712.

Experimental autoimmune uveoretinitis (EAU) is a well-established model for studying uveitis in humans. It is a CD4<sup>+</sup> T lymphocyte-mediated disease in which macrophages play an important role as effector cells of the intraocular inflammation. To induce EAU, laboratory animals are immunized with retinal autoantigens, such as S-Antigens. This experimental model has been used to evaluate the effect of drugs, which now are successfully used in humans. Some of these agents are used currently in clinical practice (e.g. corticosteroids, cyclosporine), however, these therapies are frequently complicated by systemic side effects. In such a S-Ag-induced EAU in rats, we tested the efficiency of an intravitreal injection of tamoxifen, a non-steroidal estrogen receptor modulator. To avoid side effects observed when tamoxifen is used in high doses and/or for long periods of time, we encapsulated tamoxifen into nanoparticles before administration to rats with EAU. We first investigated the localization of the nanoparticles within the eye using fluorescent labeled PEG-coated nanoparticles after injection into the vitreous cavity of rats with EAU. Whereas the injection of free tamoxifen did not alter the course of EAU, intravitreal injection of tamoxifen loaded into nanoparticles resulted in significant diminished ocular infiltration by inflammatory cells. So, the interaction of tamoxifen with estrogen receptors in macrophages could have altered the antigen presentation. In addition, there was a switch to regulatory Th2 type of response which is more protective for the eye. Our results suggest that tamoxifen, released continuously from ocular cells, could reach the immune system through the blood, thus reducing the uveitis activity.

In conclusion, the use of intravitreal administration of tamoxifen loaded onto nanoparticles allowed us to decrease the amount of the drug delivered: 250 ng/eye compared to 200-800 ng/mice in other experimental disorders. This should reduce possible ocular side effects as observed after systemic administration of high doses of tamoxifen. Although new drugs with unique therapeutic properties may be discovered and synthesized, their administration

# Physicians and Uveitis

for the purpose of treating ocular inflammation remains a major challenge. The encapsulation of biologically active molecules may increase their bioavailability and may induce a sustained release, thus avoiding repeated intraocular injections.



*Fig.: 3rd experimental Award – from the left to the right side:  
Manfred Zierhut (Tübingen / DUAG), Yvonne de Kozak (Paris),  
Hans-Jürgen Werndt (Bausch & Lomb)*

# Physicians and Uveitis

## The clinical Uveitis - Awards

### 1<sup>st</sup> award

Rothova A, Berendschot TT, Probst K, van Kooij B, Baarsma GS.

**Birdshot chorioretinopathy: long-term manifestations and visual prognosis**

Published in: *Ophthalmology* 2004; 111: 954-959.

In this research project, two uveitis research groups from large centers collaborated in order to examine long term prognosis of a puzzling ocular disorder called birdshot chorioretinopathy (BCR).

BCR is an intriguing ocular disease of unknown origin, associated with a special genetic characteristic human leukocyte antigen (HLA), the HLA-A29. BCR usually causes chronic inflammation in both eyes of middle aged persons and might lead to severe loss of central visual acuity as well as to restricted visual fields. Previous studies on BCR were of short term duration and reported that despite the chronicity of the disease, the prognosis was mostly favorable. Therefore, the treatment with immunosuppressants was recommended only during the process of losing visual acuity. However no information was available on the effectiveness of these drugs, long-term visual prognosis and on the natural course of the disease.

In our study we examined the clinical characteristics and outcomes of patients and attempted to evaluate the usefulness of standard treatments. Also we wanted to identify characteristics of BCR patients with a high risk for losing visual acuity. Our study included 55 patients with HLA-A29-positive BCR, of whom 37 were followed for at least 5 years.

The main findings of the study were the following:

1. Loss of visual acuity in BCR was slow and gradual: the number of eyes with legal blindness increased from 8% at onset of BCR to 30% after 5 years and finally to 39% after 10 years of follow-up.
2. The cause of decreased visual acuity consisted mainly of edema in the macula and macular scars. Visual field defects were present in all examined patients, and were unexpectedly large in almost a half of the patients. Abnormal retinal vessels were also observed in the majority of patients.
3. Annual loss of visual acuity did not differ between untreated patients and patients treated by standard therapeutic forms.

# Physicians and Uveitis

4. In patients with macular edema the long term visual acuity was significantly lower than in patients without macular edema.
5. More than half of the patients with BCR suffered also from cardiovascular disease, mainly from high blood pressure. The patients with BCR and high blood pressure had lower visual outcome than BCR patients without high blood pressure.

The main conclusion of our study was that the visual prognosis of BCR was poor compared to patients with other types of uveitis and that the recommended therapeutic regimens have not reduced the risk for an annual loss of vision. If we want a better prognosis for patients with BCR, then we need further studies on the cause of this disease, so that a causal therapy can be developed. One of the strengths of this study was the long time during which the patients were followed and the partnership of 2 centers. The teamwork between various centers is very important while studying unusual diseases like BCR.



*Fig.: 1st clinical Award – from the left to the right side:  
Hans-Jürgen Werndt (Bausch & Lomb), Aniki Rothova (Utrecht,  
The Netherlands), Manfred Zierhut (Tübingen / DUAG)*

# Physicians and Uveitis

## 2<sup>nd</sup> award

Curnow SJ, Scheel-Toellner D, Jenkinson W, Raza K, Durani OM, Faint JM, Rauz S, Wloka K, Pilling D, Rose-John S, Buckley CD, Murray PI, Salmon M.

### Inhibition of T cell apoptosis in the aqueous humor of patients with uveitis by IL-6/soluble IL-6 receptor trans-signaling.

Published in: Journal of Immunology 2004; 173: 5290-7.

The immune system has evolved to protect the individual from a large range of infectious organisms. Although immunity is highly efficient, there can be some damage to surrounding tissues, even if they were not infected. For the majority of tissues this bystander damage does not present a problem, as the tissue can very easily repair itself. However, for a number of tissues any significant immune mediated damage could threaten the viability of the individual. For these tissues the immune response is carefully controlled and the tissues are described as having “**Immune privilege**”. The eye is a well studied example of a tissue with immune privilege. This means that any immune response occurring in the eye should be very limited, and only result in a minimal level of damage to the tissues. It is clear that uveitis contradicts the immune privileged status of the eye, with some patients suffering severe sight-threatening inflammation. Our research group is attempting to identify the pathways that are altered during the immune response in uveitis.

One key feature of inflammation in any tissue, including the eye, is the accumulation of cells of the immune system, especially lymphocytes. Under normal conditions lymphocytes entering the eye should not persist, instead they should undergo a type of cell death termed “**apoptosis**”. We examined lymphocytes isolated from the aqueous humour of uveitis patients but could find no evidence for these cells entering apoptosis. This suggested that the cells were either unable to enter apoptosis properly, or were actively prevented from doing so. When we cultured lymphocytes with aqueous humour fluid from uveitis patients we found that apoptosis was inhibited. Importantly this did not occur for samples from non-inflamed control individuals. This indicated that the inflamed environment of the uveitis eye was actively preventing lymphocyte death. The factors responsible for this effect were identified as the cytokine IL-6 along with the soluble IL-6 receptor, both previously known to be elevated in uveitis. Our results show that in uveitis, lymphocytes that should normally die by apoptosis are protected by the inflammatory environment, leading to their accumulation. This now provides a potential new therapeutic target for uveitis.

# Physicians and Uveitis



*Fig.: 2nd clinical Award – from the left to the right side:  
Philip I. Murray (Birmingham, UK), Manfred Zierhut (Tübingen / DUAG),  
S. John Curnow (Birmingham, UK), Silke Greif (Essen / DUAG)*



*Fig.: 2nd clinical Award – from the left to the right side:  
Arnd Heiligenhaus (Münster / DUAG), Ilknur Tugal-Tutkun (Istanbul,  
Turkey) Manfred Zierhut (Tübingen / DUAG),*



# Physicians and Uveitis

## 2<sup>nd</sup> award

Tugal-Tutkun I, Onal S, Altan-Yaycioglu R,  
Huseyin-Altunbas H, Urgancioglu M.

### Uveitis in Behçet patients: an analysis of 880 patients.

Published in: American Journal of Ophthalmology 2004; 138: 373-380.

The prevalence of Behçet disease is higher in Turkey than in any other country. One third of uveitis cases seen in referral centers in Turkey are diagnosed with Behçet uveitis. In this study we retrospectively analyzed the demographic and clinical features and visual prognosis in our Behçet patients who presented with uveitis between 1980 and 1998. We included 880 patients (1567 eyes).

The disease was more common in males with a male:female ratio of 2:1. The age at onset of uveitis was around the end of the third decade of life. Male patients were significantly younger at onset and presented significantly earlier than females and with more severe disease. Ocular involvement was bilateral in 78% of the patients. Panuveitis was the most common type of involvement. Retinal vasculitis and vitritis were the most common findings of uveitis (89%) followed by retinitis (52%). A hypopyon was observed in only 12% of the eyes. The most common complication was macular edema (45%) followed by cataract (39%). An optic atrophy was observed in 24% of the eyes. Visual acuity at initial visit was 0.1 or less in 41% of the eyes. However, since visual acuity may be severely affected during inflammatory episodes and may improve when the inflammation resolves, we defined potential visual acuity as the best visual acuity recorded during the first remission period at the beginning of follow-up. Potential visual acuity was 0.1 or less in 31% of the eyes in males and 24% of the eyes in females. Thus male patients had more severe disease from the onset of uveitis. We found that 15.6% of the eyes with a potential visual acuity better than 0.1 lost useful vision irreversibly during follow-up. We estimated the risk of loss of useful vision to be 6% at 1 year, 17% at 5 years, 25% at 10 years, and 29% at 20 years. The risk of losing vision was significantly higher in males than in females. However, male patients who presented after 1990 had a significantly lower risk of losing vision than male patients who presented before 1990. Although there was a similar trend in females as well, a significant difference was not found, probably because the natural disease course is milder in females. Only conventional immunosuppressive agents were used during the study period. However, there were changes in our therapeutic approach. In the 1980s we first treated

# *Physicians and Uveitis*

the patients with corticosteroids and administered immunosuppressive agents when long-term high-dose corticosteroids were required. Cyclophosphamide was the initial drug of choice during that period. In the 1990s we tried to avoid corticosteroid monotherapy in patients with posterior segment involvement and administered immunosuppressive agents early in the follow-up. The initial drug of choice was azathioprine. Cyclosporine was available only during the second half of the study period. Therefore, we speculated that our more aggressive therapeutic approach in the 1990s and availability of cyclosporine had improved the visual prognosis in our patients. We believe that visual prognosis may further improve with the use of new immunomodulators and biologic agents. A study comparing patients who presented in the 2000s with those who presented in the 1990s is currently underway at our department.



## Uveitis – A Look back into 1910

*Uveitis is not a new disease, its clinical course has been known for a long time. Phil Hibbert, who runs the UIG, the patient uveitis group in the UK, has found interesting information about the role, uveitis played app. 100 years ago.*

I am sure that Ophthalmologists and patients would agree that one of the major concerns with uveitis is its place in the field of Ophthalmology. This ‘medical’ condition seems to sit uncomfortably in the mainly ‘surgical’ world of Ophthalmology. This appears to result, in many instances, in a lack of a good route for the patient with uveitis; from patient presenting at their general practitioner through to referral to a suitable specialist to manage the condition.

It was with this in mind that I thought it would be interesting to see how uveitis was managed many years ago.

To get some idea, we can go back to a text published in 1910, “The Modern Physician”, edited by Dr. Andrew Wilson, the rather severe looking gentleman pictured besides to give a flavour of the times.

This publication, although considered a ‘medical text book’ was also probably a forerunner to the ‘popular science’ books of today. It consists of five volumes and has some highly entertaining, politically incorrect and / or gruesome reading. A look at the eye conditions chapter proved very interesting.



*Dr. Andrew Wilson*

There is a section titled ‘Iritis’. There is no mention in the book of posterior uveitis as such but sympathetic ophthalmia is covered as a separate section. Interestingly, the ‘Iritis’ section took prominence over two much smaller sections, ‘Cataract’ and ‘Glaucoma’. Another prominent section here was the serious matter of burns with slaked lime, a reminder of how widespread the lime industry was at this time.

## Cultural Corner

Looking closer at the 'Iritis' section it is striking to see what importance was given to this condition.

**"It is a most serious ailment, and one that demands prompt and efficient treatment. It is only mentioned here to emphasise its importance, and no one unskilled in the treatment of eye affections should undertake such a case if special treatment can be obtained."**

It seems that anterior uveitis was considered to be a condition which required very prompt treatment and by someone experienced in its management. This echoes modern ideal standards and yet uveitis specialists and patients still frequently report very late or missed diagnosis and inappropriate or no referral.

The next paragraph of interest seems to describe the clinical picture closely. This appears accurate even compared to modern knowledge and it does demonstrate the importance held at that time of differentiating the diagnosis from other conditions such as conjunctivitis.

**"Symptoms: The eye is red and painful, the pain frequently shooting above the eye and into the nose. The redness differs from that of conjunctivitis in that it is most intense round the "sight" of the eye, there frequently being an intense purplish-red halo around it. The pupil is usually smaller than that of the other eye, and often irregular**

**in shape. If shaded from the light it does not dilate or expand so easily as that of the unaffected eye."**

The section of the old text book on treatment shown below demonstrates how far treatment has come since the early 1900's. We can see from the section below that the treatment options are pretty limited and apparently a bit extreme in some cases.

**"The Treatment of Iritis must be undertaken promptly to be successful, and it will consist of the application of atropine dropped into the eye two or three times a day. Dry or moist heat may be frequently applied in the form of compresses (not poultices), and if the pain is severe or the pupil not dilating well, one or two leeches applied to the temple of the affected side may give wondrous relief."**

However it is worth noting the reference to hot compresses, a method which possibly is undervalued today, and a method certainly encouraged by some uveitis specialists and specialist uveitis nurses. One UK uveitis specialist has become involved in the manufacture of microwavable compresses, ('The Eyebag'). I'm not aware of any specialists advocating the use of leeches but I suppose we should keep an open mind.

References:

"The Modern Physician" edited by Dr Andrew Wilson and published in 1911.

# *Patient Groups & Information*



# *Patient Groups & Information*

## **Uveitis Information Group**

**A patient led information and support group.**

---

### ■ **Activities**


- Provision of information and support by letter, phone and email.
- Public meetings around the UK.
- Web site

### ■ **To Contact:**

**POST:** UIG, South House, Sweening. Vidlin, Shetland Isles, ZE2 9QE

**EMAIL:** [info@uveitis.net](mailto:info@uveitis.net)

**WEBSITE:** [www.uveitis.net](http://www.uveitis.net)



*uveitis* appears once a year – in German, French and English language  
Free for members of the national uveitis patient interest groups

**Circulation:** 4300 copies for the English edition (in total 26.000 copies)

**Editor for the English version:** **Uveitis Information Group**

**Contact:** Phil Hibbert, South House, Sweening. Vidlin, Shetland Isles, ZE2 9QE

**Phone:** +44 (0)1806 577310 **Email:** info@uveitis.net **Website:** www.uveitis.net

**Overall Editor:** Manfred Zierhut

**Editorial Office:** Jutta Grimm, Phil Hibbert, Matthias Nahm, Chris Parkin,  
Carlos Pavesio, Chris Rodgers, Manfred Zierhut

**Cheques may be payable to Uveitis Information Group.  
Outside the UK, please contact the UIG.**

■ *Articles in this journal reflect the opinions of the authors and not necessarily of the editorial office.*

Hydrates, lubricates and protects the ocular surface

# HYABAK<sup>®</sup>

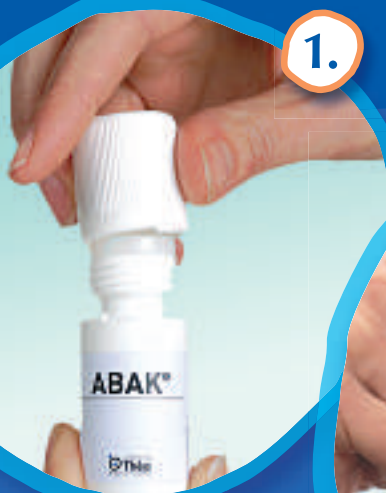Sodium hyaluronate 0.15 %

Medical device

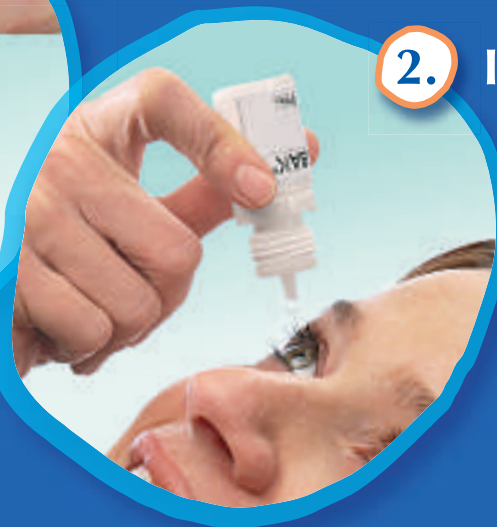All the hyaluronic acid features  
in the ABAK BOTTLE<sup>®</sup>



1. OPEN



2. INSTIL ... that's all!



● Callibrated drops and controlled instillation

● 10 ml preservative free bottle

● 8 weeks of use after the first opening

● 1 drop in each eye during the day  
as often as necessary

